

Clinical Case Studies

More than just reducing odor and symptoms caused by bacteria and fungus, the CuTEC™ technology enhances the appearance of skin texture, tone and skin wellness for the wearer.



Investigation by:

Richard Zatcoff D.P.M.

Chief Medical Officer, Next Fiber Technology

DABPS, FACFAS, FACFAOM

Case Studies

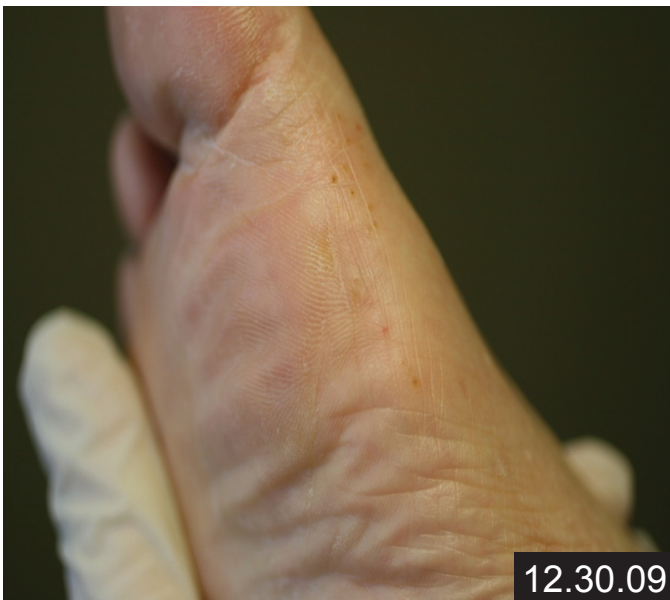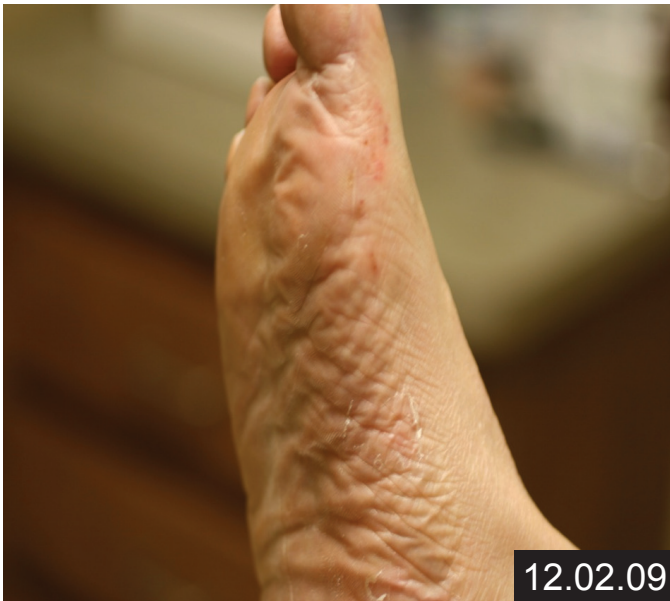Medicore Socks

Case Study

Patient # 7561

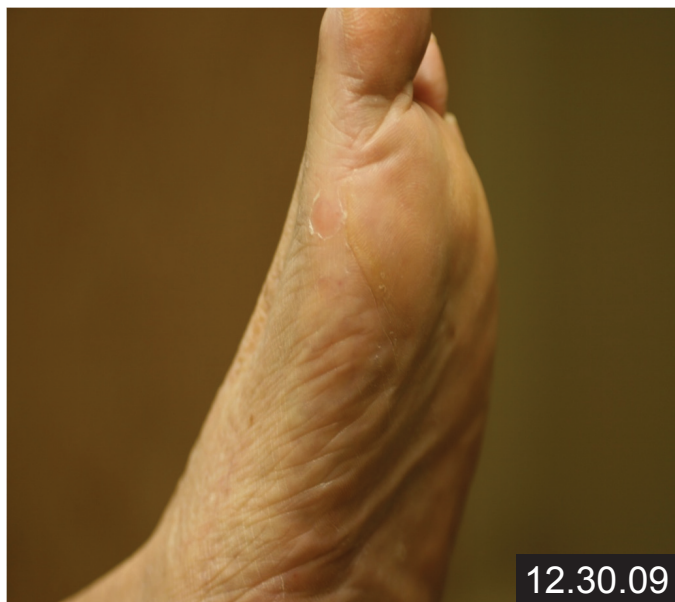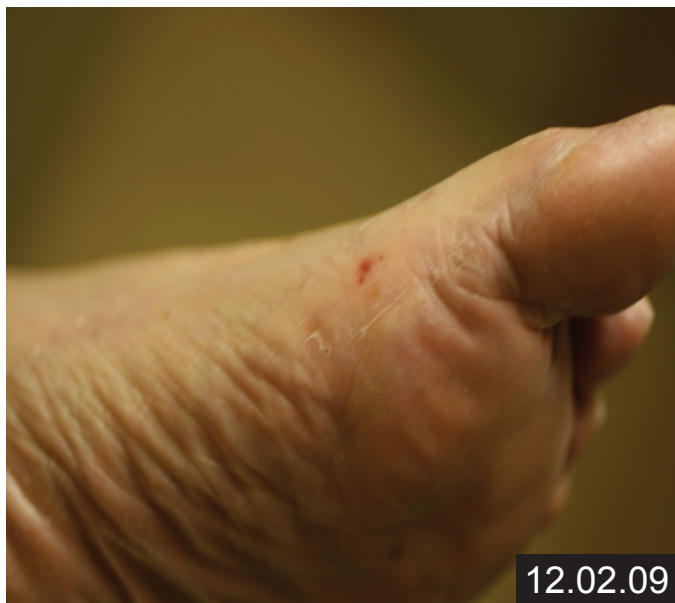73 year old male with 9 year history of diabetes, hypertension, cardiovascular disease with stent placement in 2003. The healing power of the Medcore socks with CuTEC™ technology enhances the skin quality and wellness for the wearer. Mild to moderate Athlete's Foot improved by Medcore CuTEC™ sock wear.

(continued on page 4)



Case Study

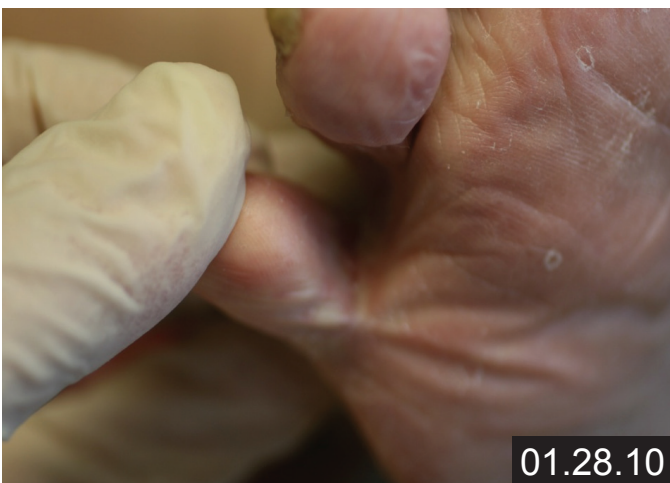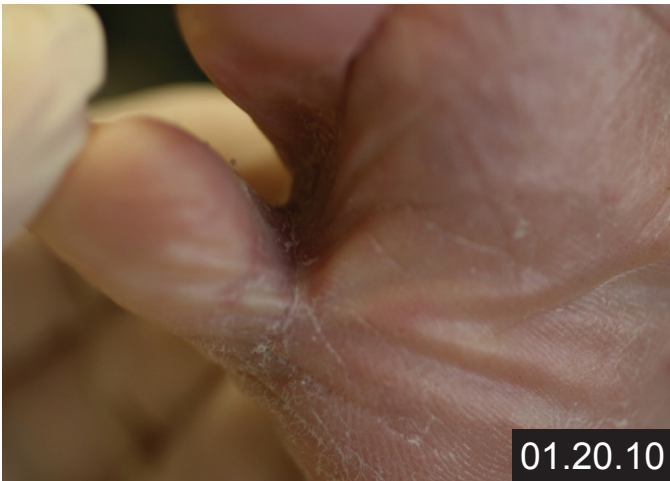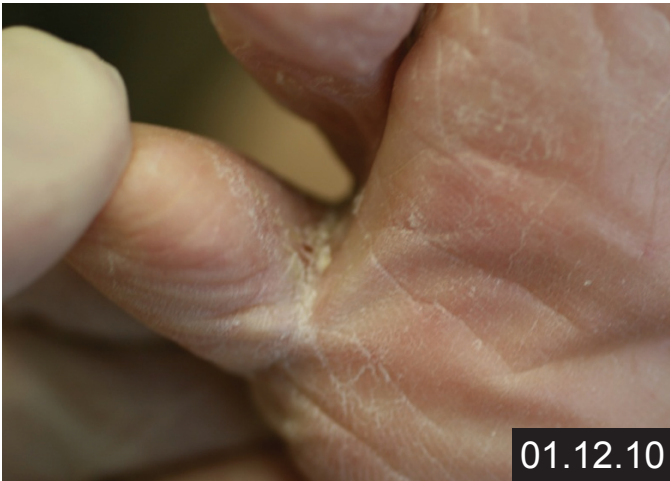Patient # 7561 (continued)



Case Study

Patient # 9057

89 year old male with history of hypertension, and cardiovascular disease. Chronic athlete's foot improved by Medcore CuTEC™ sock wear.

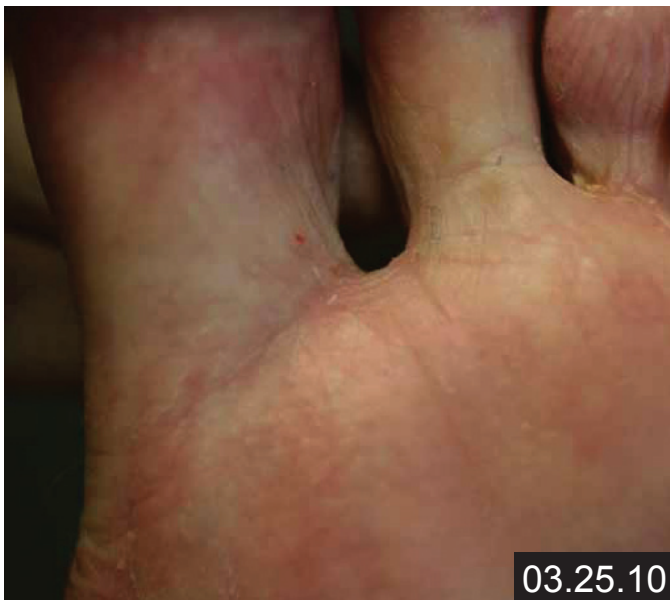
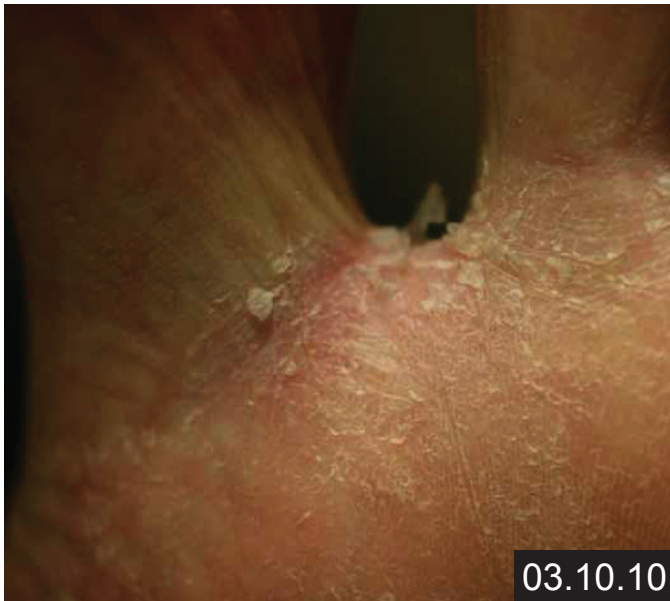
Case Study

Patient # 12236

79 year old male. 6 year history of diabetes, along with hypertension, and cardiovascular disease. Patient presents on 3-10-10 with tinea present to the plantar aspect and interdigital aspect of both feet. Medicores CuTEC™ socks dispensed to patient this date. Improvement observed on 3-25-10.

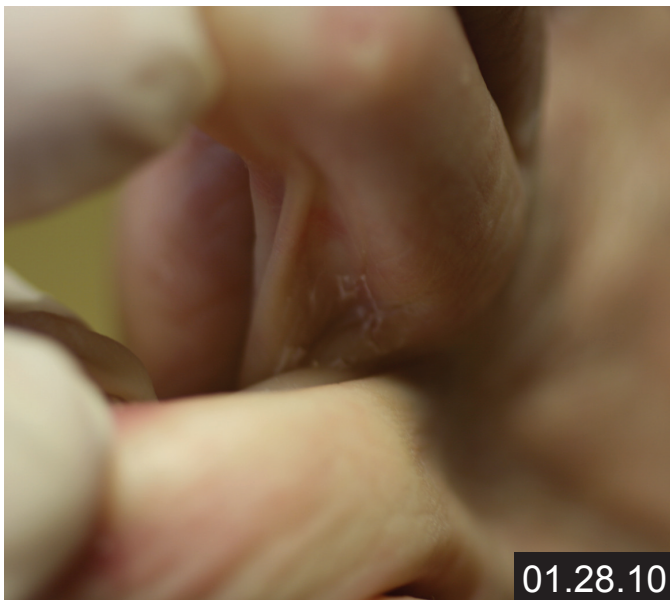
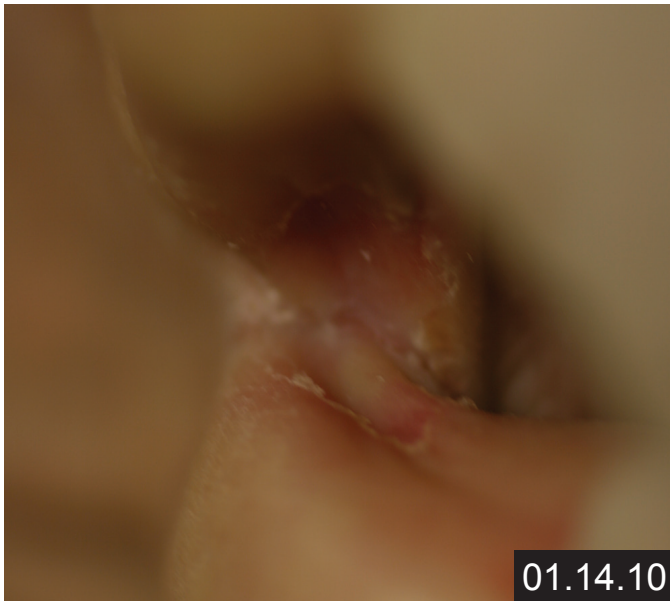
Excellent improvement to scaling and skin tone after only 2 weeks of Medicores CuTEC™ sock wear.



Case Study

Patient # 7848

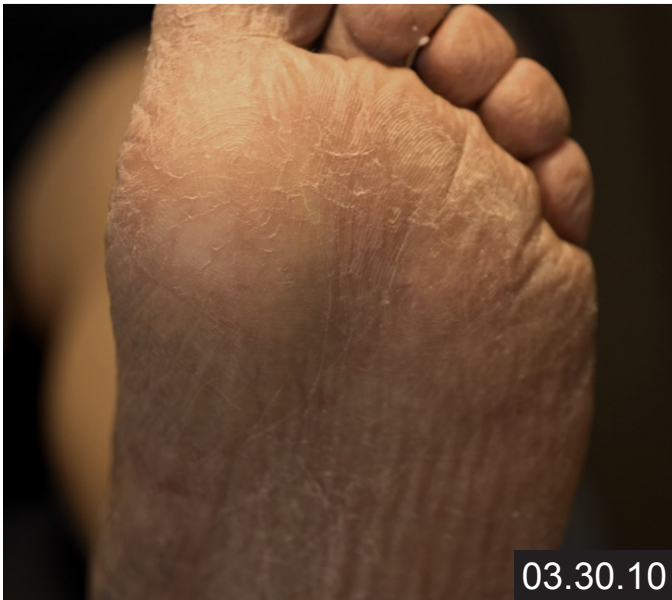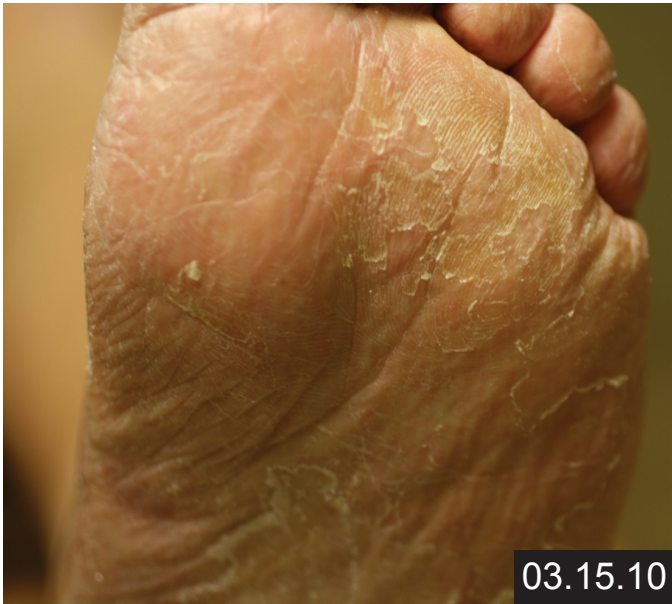84 year old male with multi year history of hypertension and cardiovascular disease including cardiac syndrome in 2001. Acute interdigital athlete's foot before and after treatment with Medcore CuTEC™ socks.



Case Study

Patient # 11722

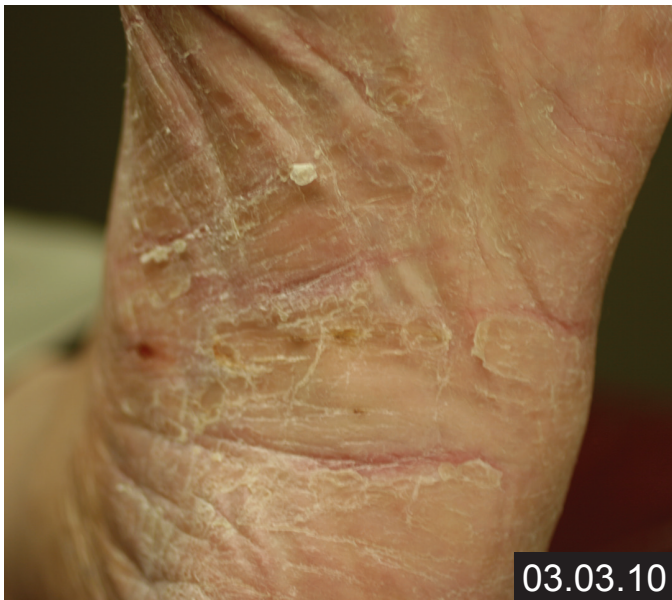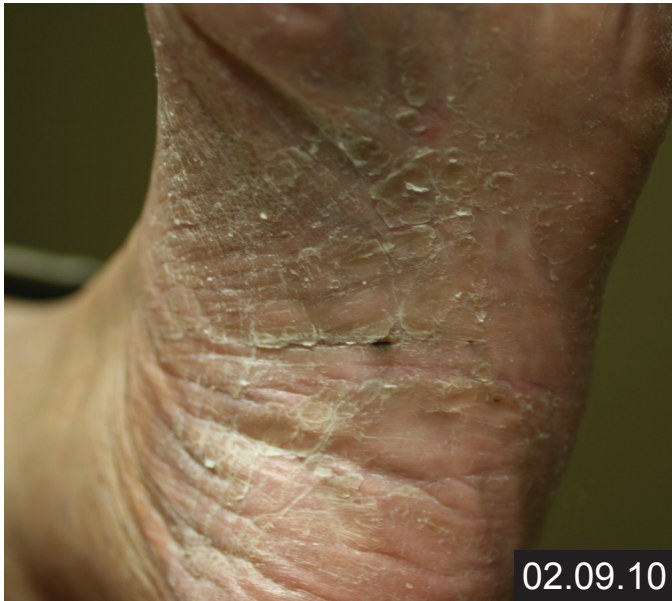73 year old male with multi year history of diabetes, hypertension, and high cholesterol. Chronic athlete's foot bottom of left foot, improved by Medcore CuTEC™ sock wear.



Case Study

Patient # 11847

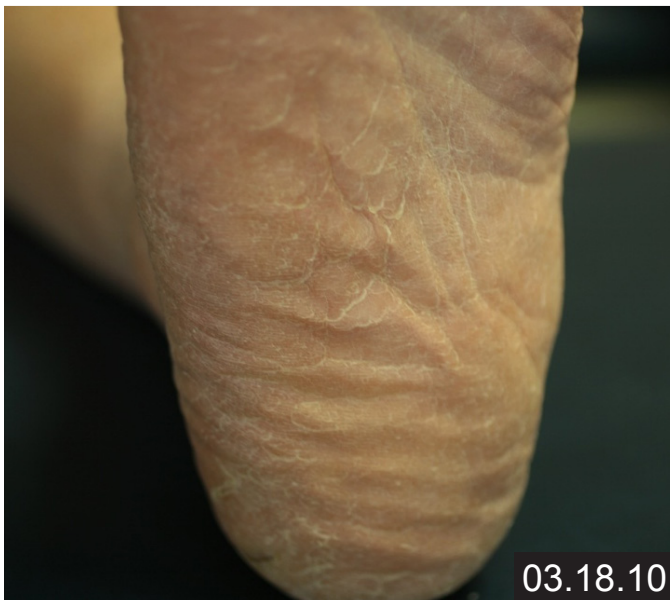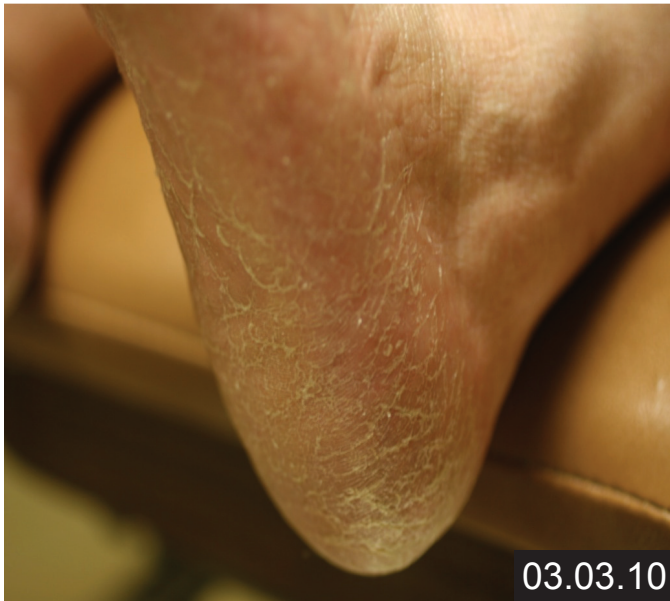90 year old male with chronic scaling caused by athletes foot, improved with Medcore CuTEC™ sock wear.



Case Study

Patient # 12364

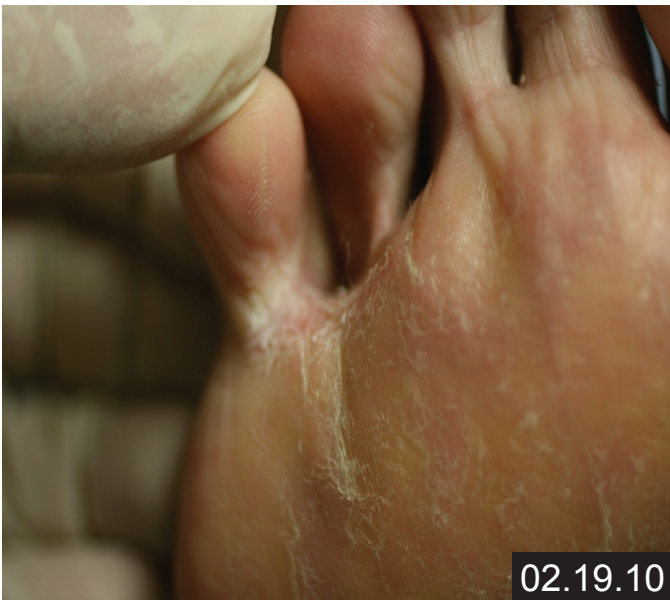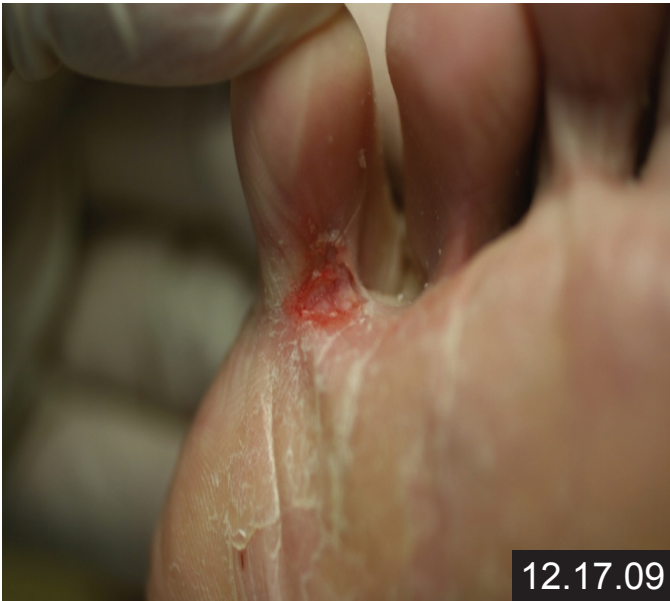69 year old male with 12 year history of diabetes and hypertension. Dramatic improvement of scaling and skin tone improved with Medicores CuTEC™ sock wear.



Case Study

Patient # 13607

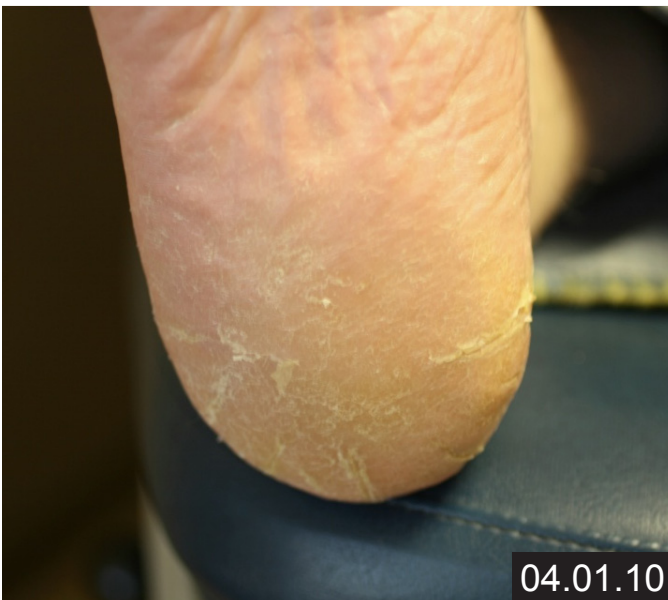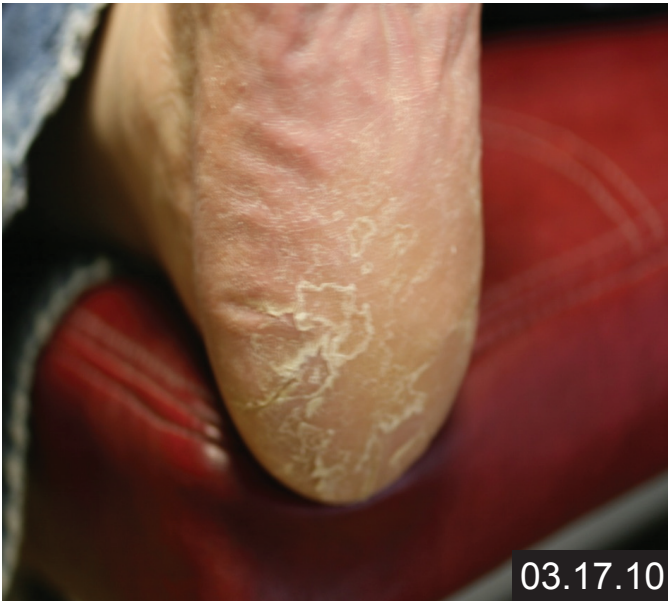45 year old male with history of hypertension. Chronic athlete's foot improved with Medcore CuTEC™ sock wear.



Case Study

Patient # 12312

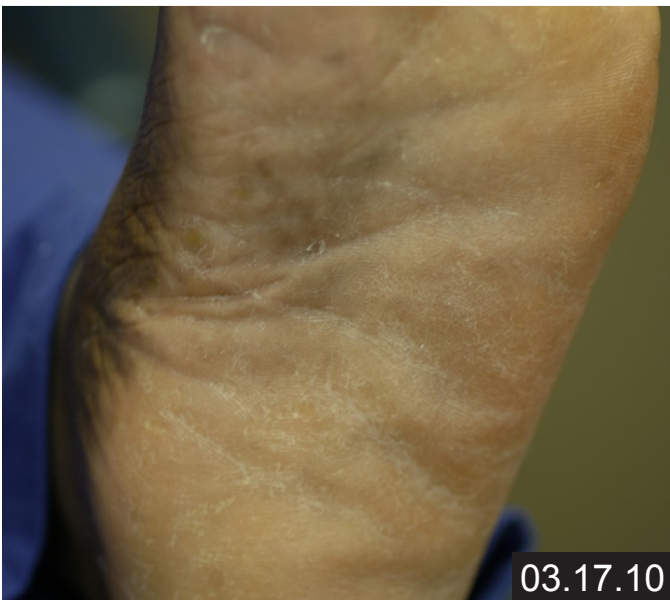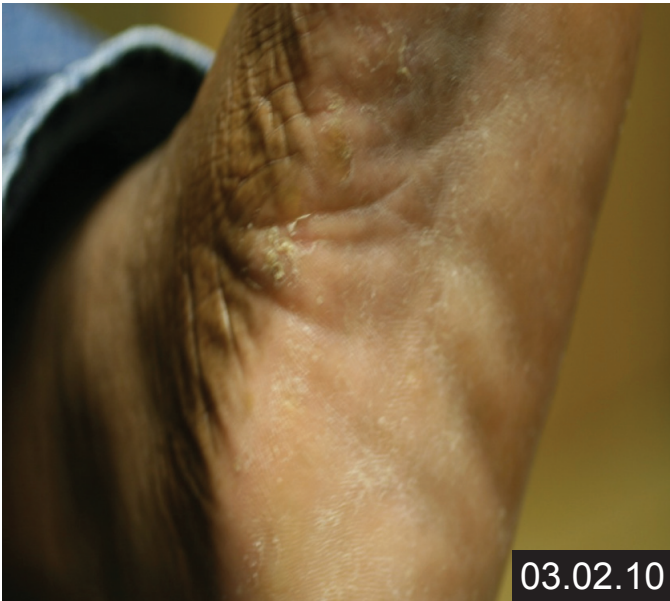51 year old male. Chronic athlete's foot improved with Medcore CuTEC™ sock wear.

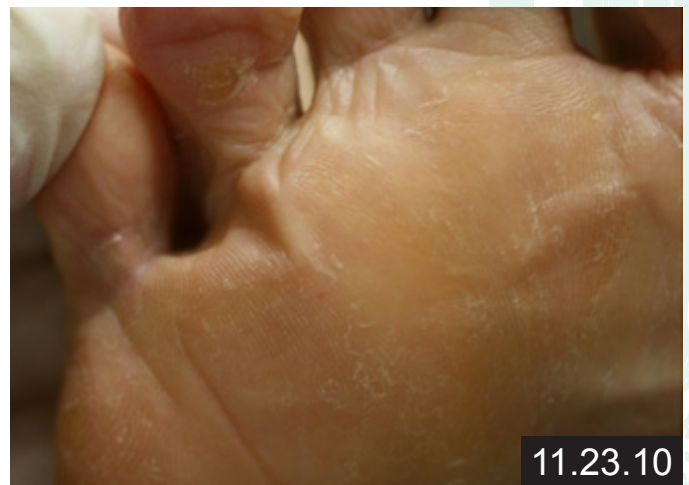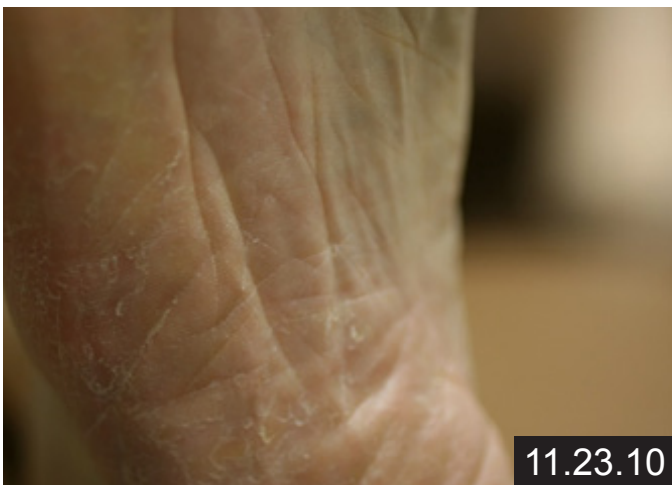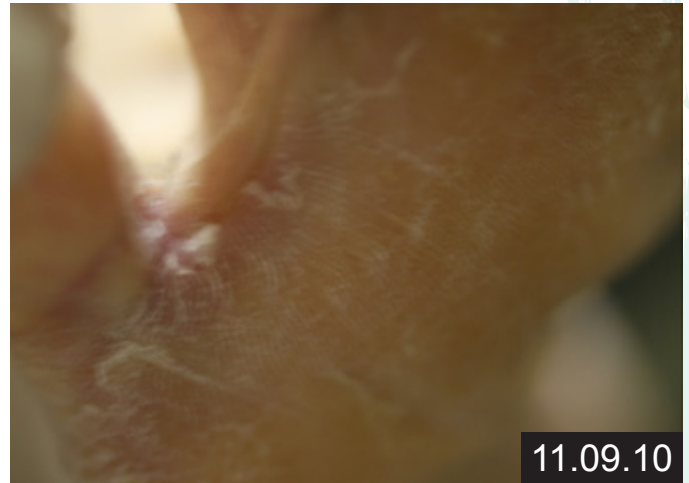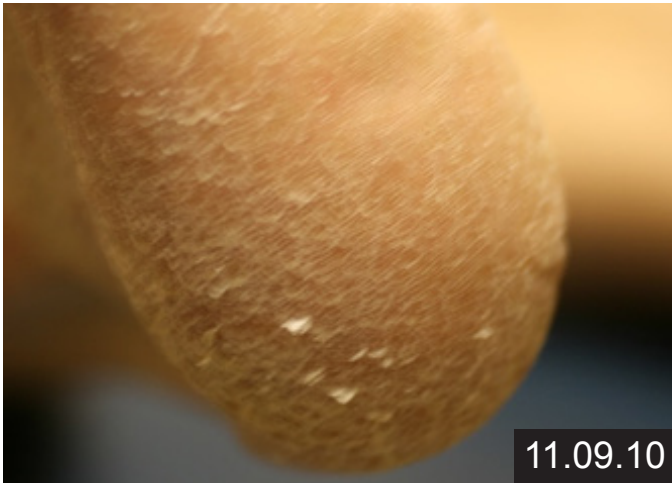


Case Study

Patient # 13753

45 year old female. Improved skin tone and decreased scaling in only 2 weeks with Medcore CuTEC™ sock wear.





Case Study

Patient #1786

56 year old male. Several month history of tinea present to the plantar and interdigital aspect of both feet. CuTEC™ socks dispensed on 11-9-10. Excellent results noticed especially interdigitally on 11-23-10.



Case Studies

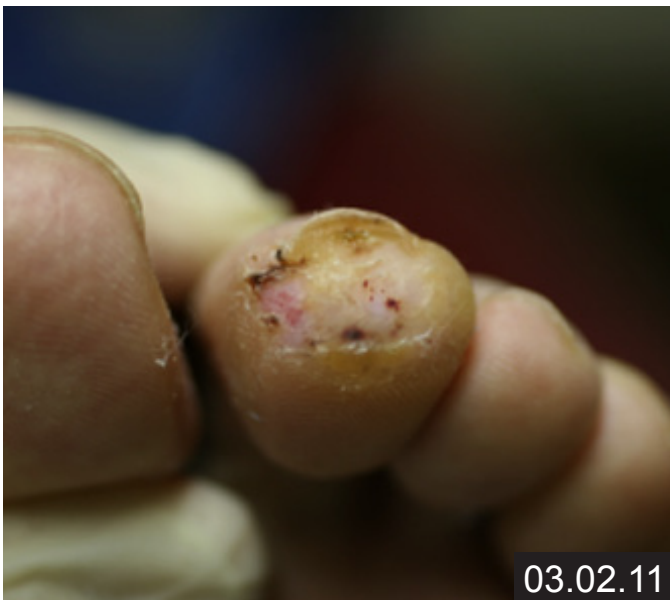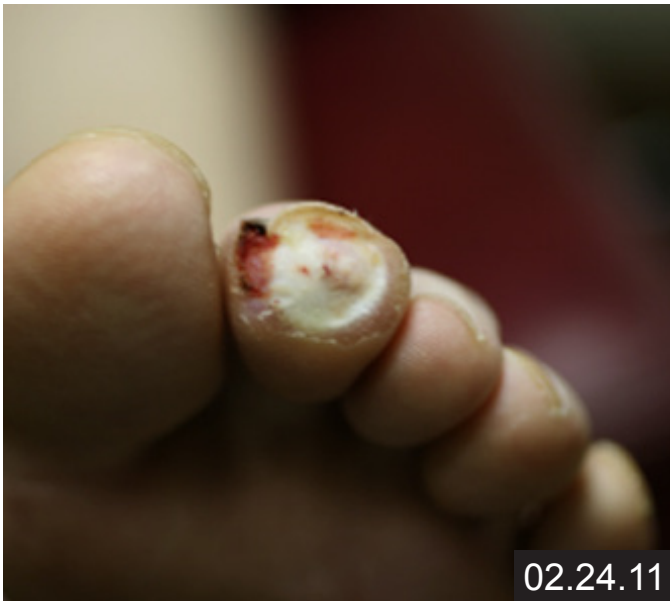Medicore Wound Dressing



Case Study

Patient # 2796

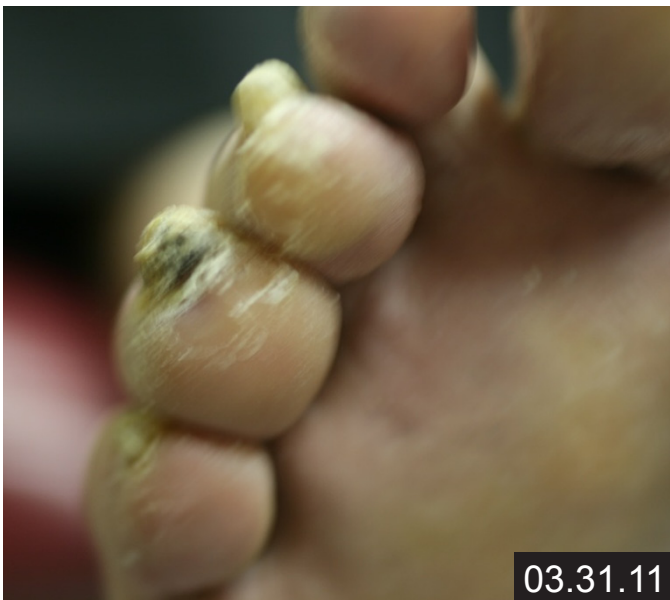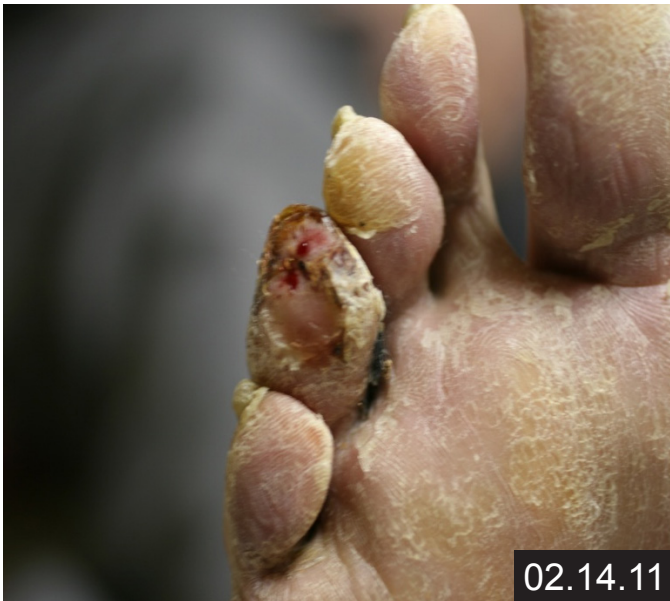64 year old male. Multi year history of diabetes. Prior history of R/BK amputation. Patient presents with ulceration to tip of 2nd toe left foot. Ulcer measures 1.3 x 1.0 cm on 2-24-11. Medcore CuTEC™ dressing applied to area. Ulceration well healed on follow-up visit 3-2-11.



Case Study

Patient # 10466

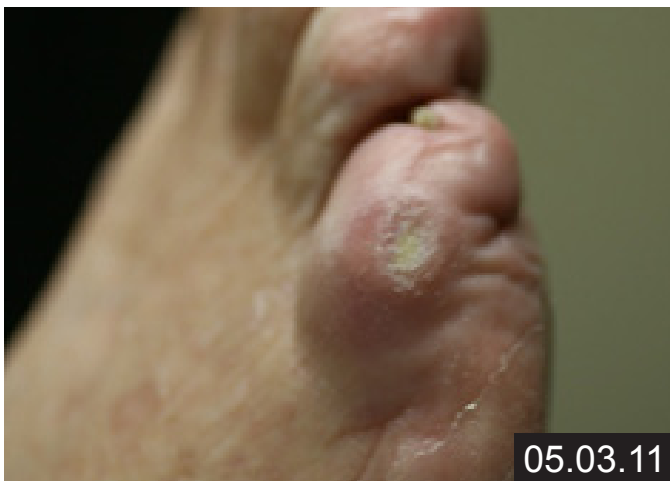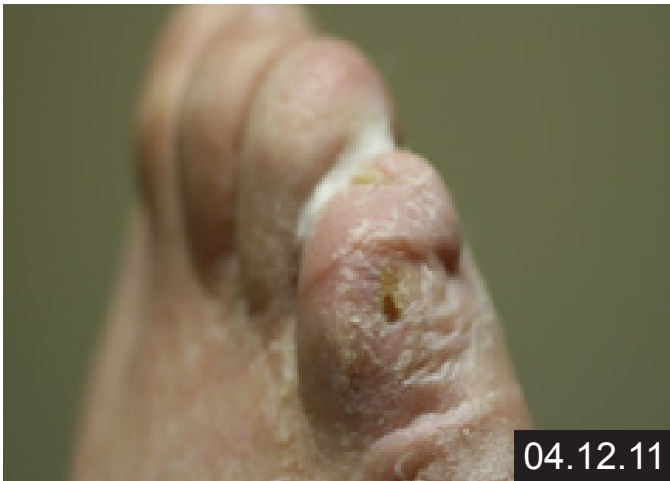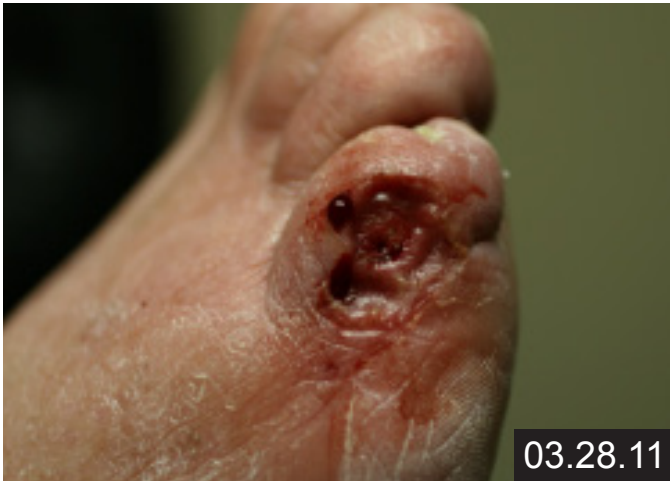80 year old male. Sixteen year history of diabetes, hypertension, and cardiovascular disease. Patient presents on 2-14-11 with an ulceration to the 4th toe right foot. Application of Medcore CuTEC™ dressing this date. Ulceration is well healed on 3-31-11.



Case Study

Patient # 8562

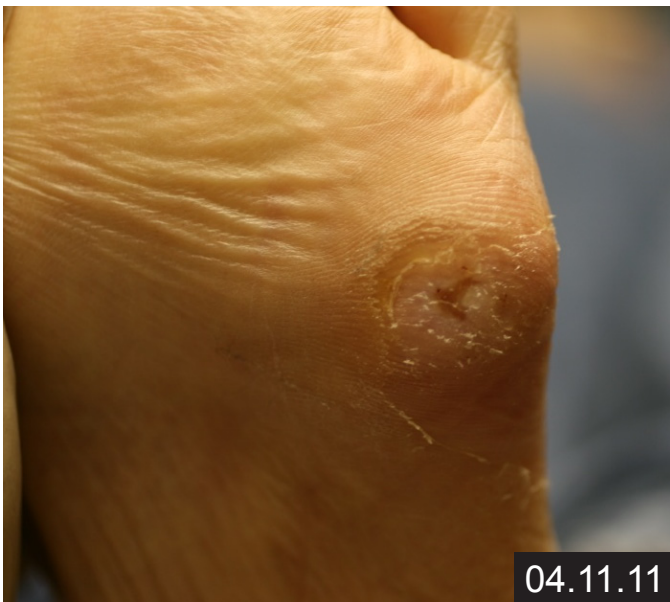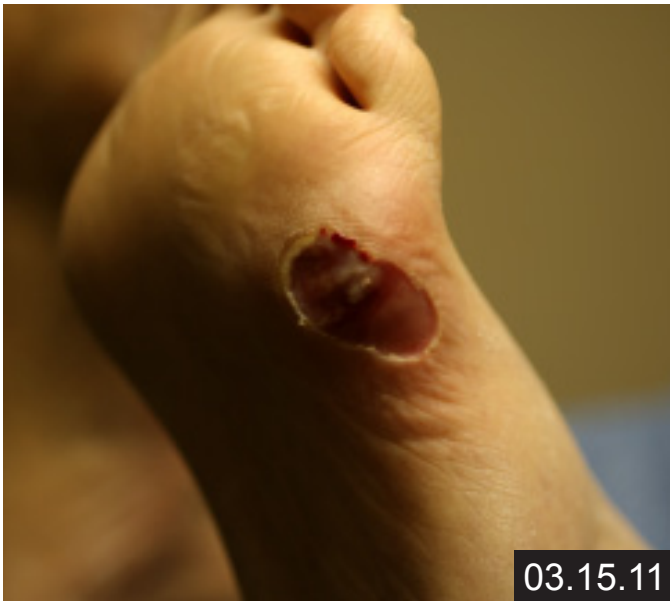77 year old female. Multi year history of neuropathy of unknown cause. History of left hallux and 2nd toe amputations. Patient presents on 3-28-11 with an ulcer to her right 5th toe with exposed bone. Medcore CuTEC™ dressing applied this date. Ulcer is well healed on 5-3-11.

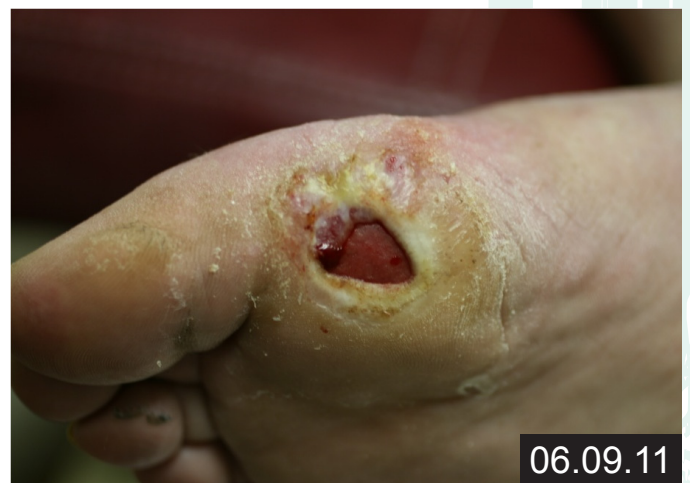
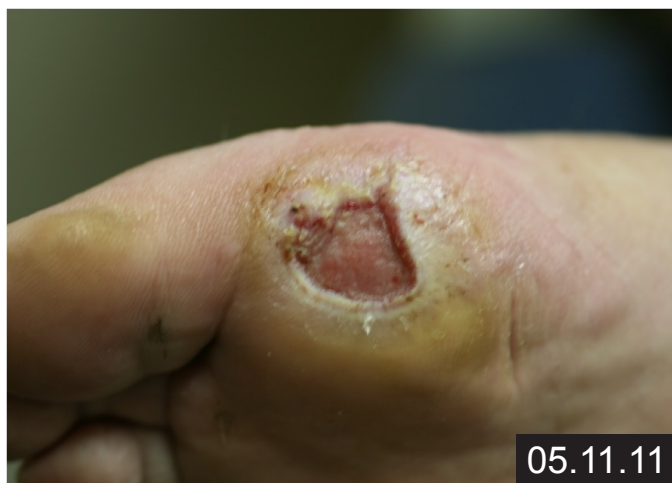
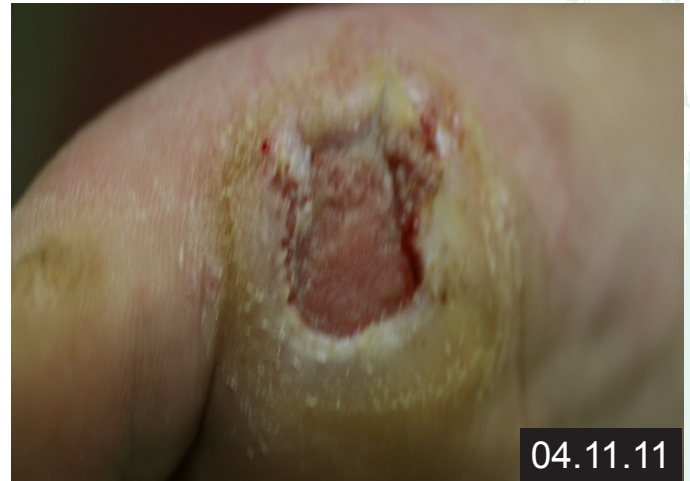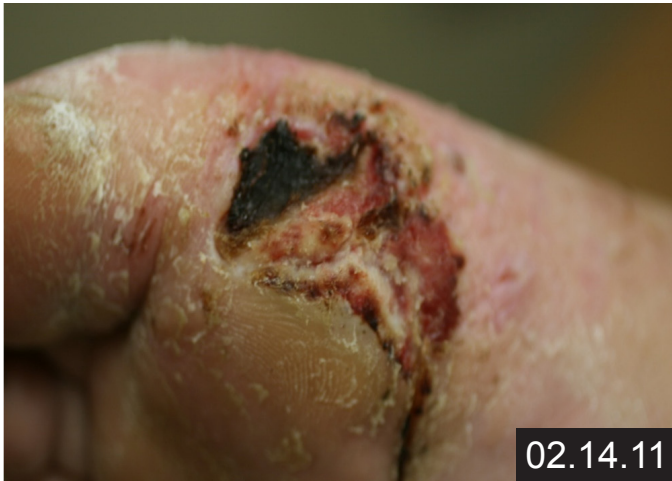Case Study

Patient # 1854

67 year old male. Multi year history of diabetes, hypertension, cardiovascular disease, and peripheral neuropathy. Left 5th MPJ ulcer present on 3-15-11. Measures 2.8 x 1.2 cm. Medcore CuTEC™ dressing applied this date. Ulcer closed on 4-11-11.





Case Study

Patient # 13363

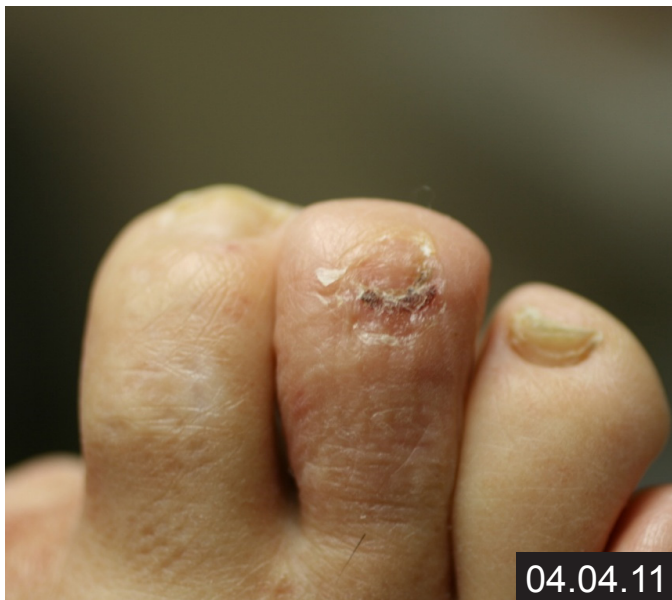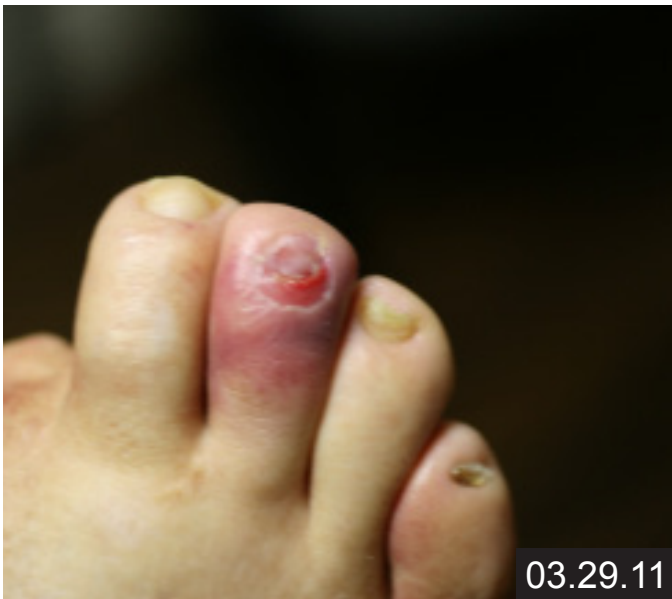70 year old female. Twelve year history of diabetes, hypertension, and cardiovascular disease. Patient presents on 2-14-11 after hospitalization for cellulitis and ulceration on right foot. Medcore CuTEC™ dressing applied this date. Ulcer shows improvement 6-9-11.



Case Study

Patient # 5730

53 year old male. Eighteen year history of diabetes, hypertension, cardiovascular disease, kidney disease, and R hallux amputation. Patient presents on 3-29-11 relating that he hit his right 3rd toe on a door leading to loss of that nail. Medcore CuTEC™ dressing applied to infected area. Toe is well healed on 4-4-11.

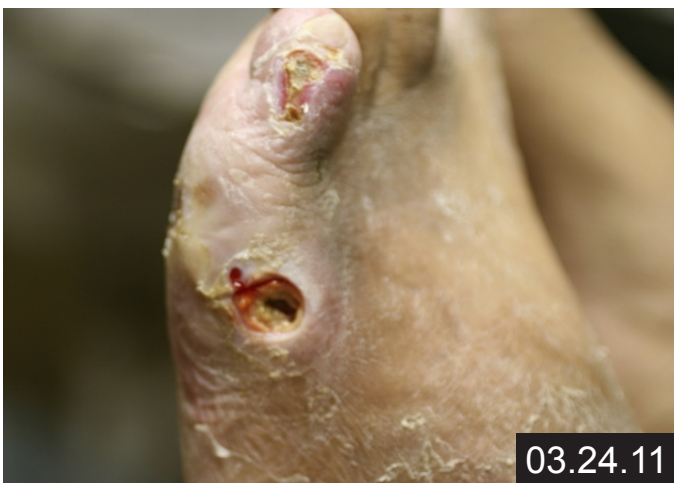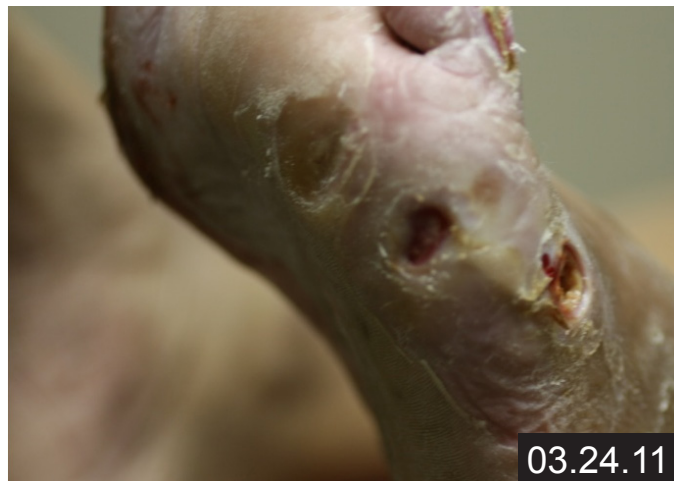

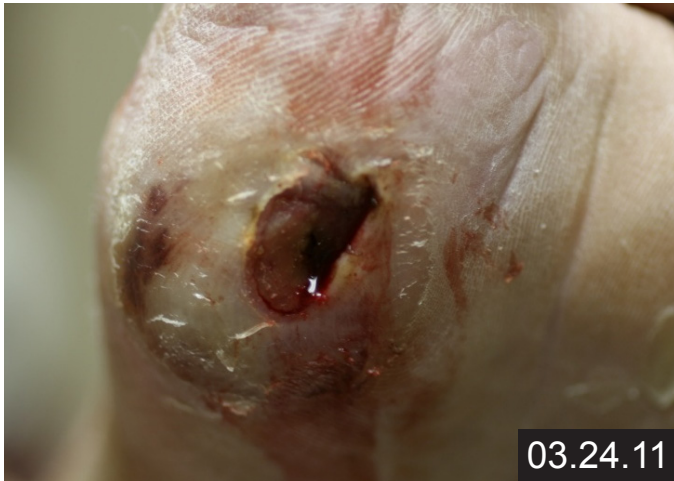
Case Study

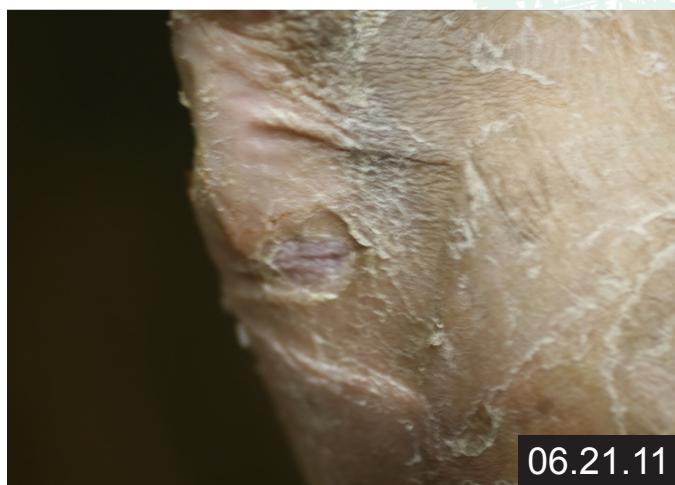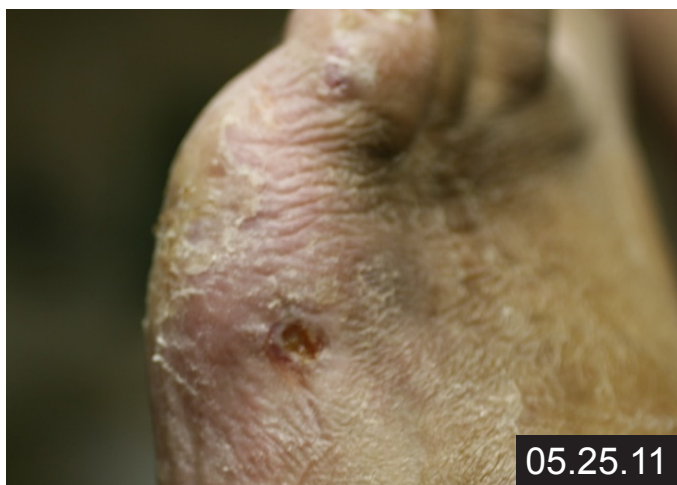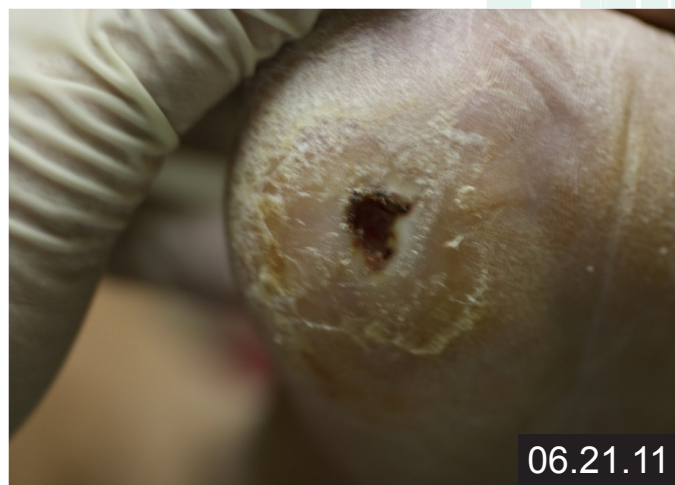
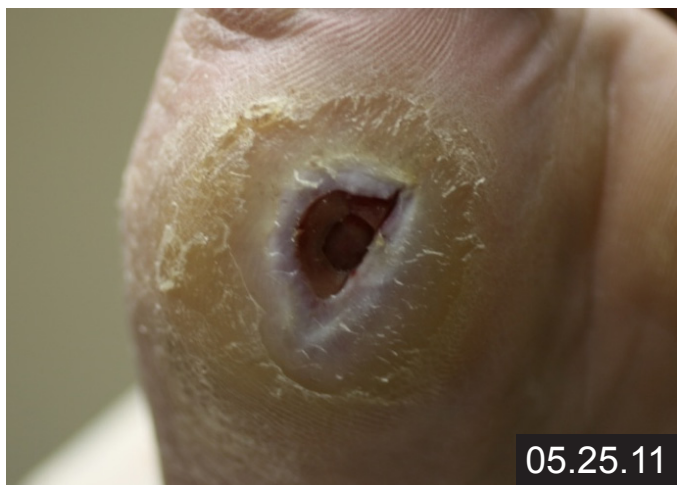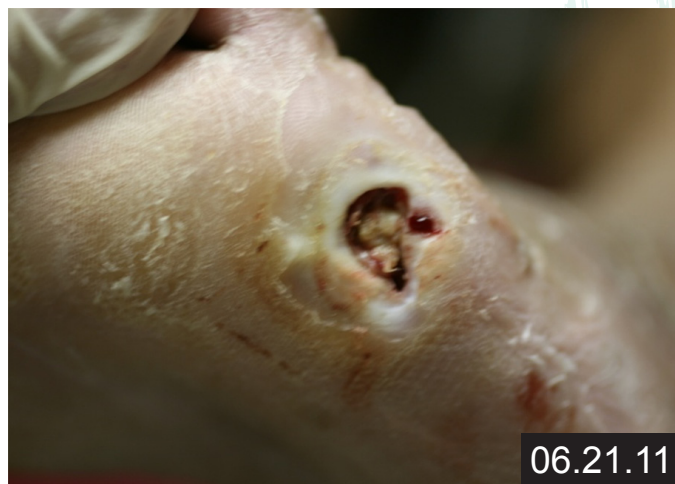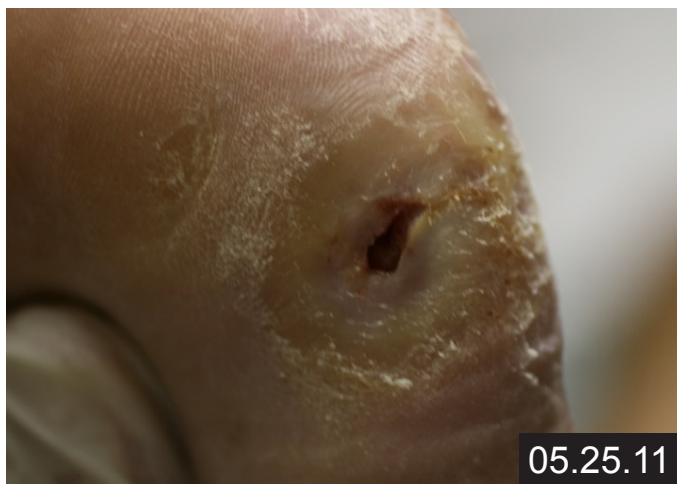Patient # 5730

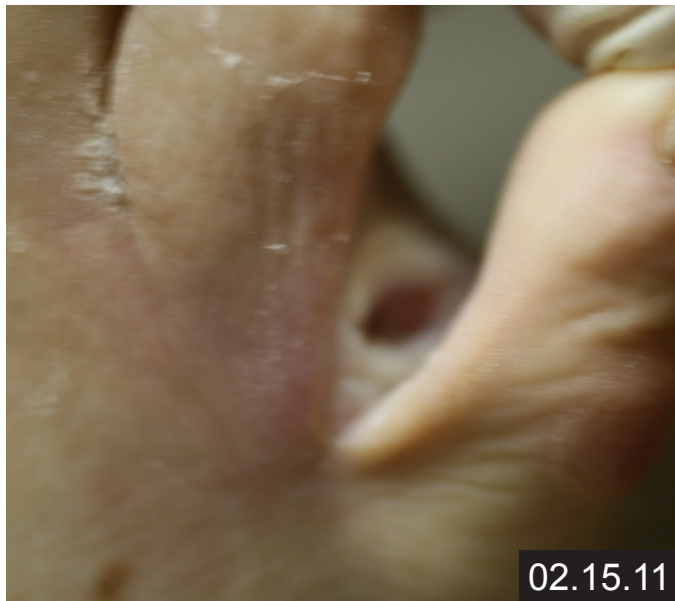37 year old male, diabetic, kidney disease, HIV positive, hypertensive, cardiovascular disease, and history of stroke. History of right 4th and 5th toe amputation in 2004. Second toe left foot amputated in 2008. Patient presents 3-24-11 c/o a 3 month history of ulceration to the left 1st and 5th MPJ region. First MPJ ulcer measures 1.0 x 1.5 cm this date, the 5th MPJ plantar ulceration measures 1.1 x 0.4 cm, and the 5th MPJ dorsal ulcer measures 1.0 x 1.0 x 0.5 cm with significant drainage and ability to probe to bone. Medcore CuTEC™ dressing was applied to all areas. Most recent visit on 5-25-11 shows the 1st MPJ ulceration measures 10.0 x 8.0 mm, the plantar 5th MPJ ulcer measures 5.0 x 2.0 mm, and the dorsal 5th MPJ ulcer measures 2.0 x 2.0 mm.

(continued on page 23)



Case Study Patient # 14418 (continued)

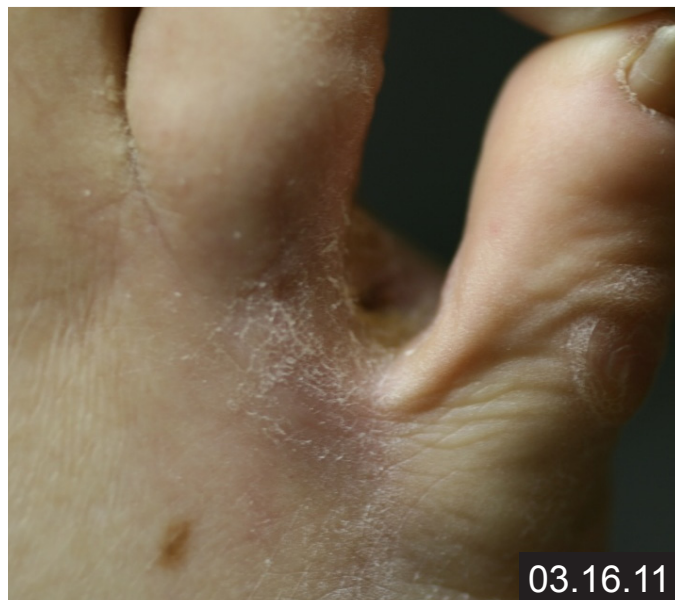



Case Study

Patient # 2023

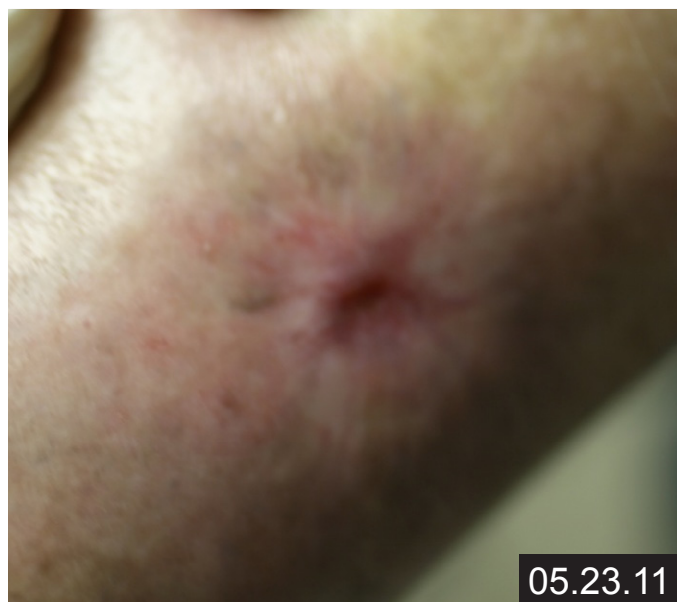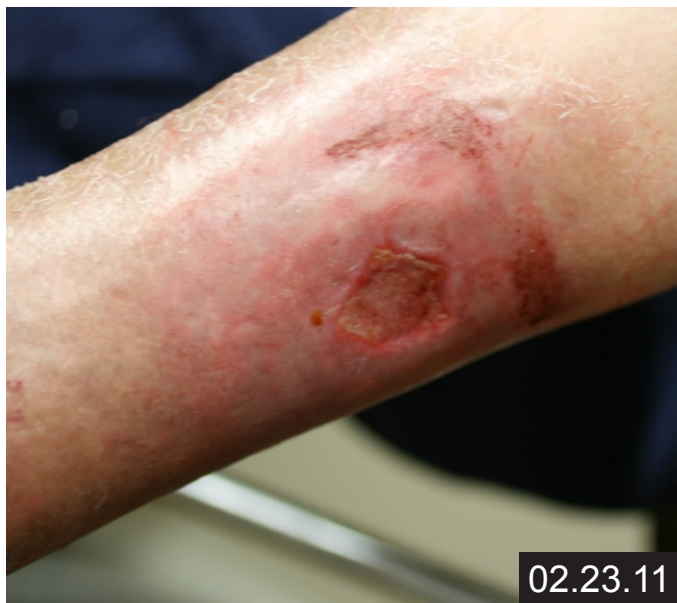66 year old male with multi year history of hypertension, cardiovascular disease, peripheral neuropathy, and charcot arthropathy. Patient has multi year history of foot problems including ulcerations, osteomyelitis, and multiple surgeries. Patient presents on 2-15-11 c/o a new sore 4th is right foot. Ulcer measures 5.0 x 2.0 mms. Medcore CuTEC™ dressing applied to ulcerative area. Ulcer is well healed on 3-16-11.



Case Study

Patient # 9671

42 year old male. Twenty-two year history of paraplegia, along with multi year history of psoriasis. Patient smokes 1/2 pack per day. Three year history of left leg ulceration. Left leg ulceration measured 2.1 x 1.5cm on 2-23-11. First application of Medcore CuTEC™ dressing this date. Lesion completely closed on 5-23-11.



Case Study

Patient # 14408

57 year old male with 4 year history of diabetes and hypertension. Patient presents on 3-22-11 with an ulcer to the left 1st MPJ, present for 3 months. Medcore CuTEC™ dressing applied this date. Well healed by 06-22-11.

